CASE RECORDS of the MASSACHUSETTS GENERAL HOSPITAL

Founded by Richard C. Cabot, M.D.
Eric S. Rosenberg, M.D., *Editor*
David M. Dudzinski, M.D., Meridale V. Baggett, M.D., Daniel Restrepo, M.D.,
Dennis C. Sgroi, M.D., Jo-Anne O. Shepard, M.D., *Associate Editors*, Lindsay Maguire, *Program Manager*



Case 33-2026: A 73-Year-Old Woman with Fever, Weight Loss, and Leg Weakness

Michael P. Janjigian, M.D.,[1] Monica Cheng, M.D.,[2,3] Cory A. Perugino, D.O.,[4,5] and Jonathan S. Hausmann, M.D.[4,6]

Author affiliations are listed at the end of the article.

N Engl J Med 2026;395:2044-54.
DOI: 10.1056/NEJMcpc2603186
Copyright © 2026 Massachusetts Medical Society.

CME

PRESENTATION OF CASE

Dr. Joseph D. Nguyen (Medicine): A 73-year-old woman with a history of ductal carcinoma in situ of the right breast, which had been treated with mastectomy of the right breast and radiation therapy 20 years earlier, presented to the emergency department of this hospital with fever, weight loss, and weakness in the legs.

The patient had been in her usual state of health until 1 month before the current presentation, when edema developed in both legs up to the ankles. During the next week, the swelling extended to the midshins and was accompanied by a sensation of numbness, burning pain, and heaviness in her feet. The patient had difficulty ambulating and sustained two falls at home, without antecedent dizziness or loss of consciousness.

Three weeks before the current presentation, the patient was evaluated in the emergency department of another hospital for the falls. On examination, the vital signs were normal. Swelling was noted in both legs, extending more proximally in the right leg, and she had unsteadiness on ambulation. The blood levels of electrolytes, albumin, bilirubin, aspartate aminotransferase, alanine aminotransferase, and N-terminal pro–B-type natriuretic peptide (NT-proBNP) were normal, as were the results of kidney-function tests; the urinalysis was also normal. A complete blood count showed a hemoglobin level of 10.2 g per deciliter (reference range, 11.8 to 16.0) and a platelet count of 584,000 per microliter (reference range, 150,000 to 400,000). Other laboratory test results are shown in Table 1.

Vascular ultrasonography of the legs showed no evidence of deep-vein thrombosis. Computed tomography (CT) of the head, performed without the administration of intravenous contrast material, reportedly showed no abnormalities. The patient was evaluated by a physical therapist and was discharged home with a walker for ambulation. Follow-up with her primary care physician was recommended.

One week before the current presentation, the patient was seen at her primary care physician's office. The vital signs were normal. Edema was noted in both legs and extended to the midshins. The patient was unable to ambulate without a

The New England Journal of Medicine is produced by NEJM Group, a division of the Massachusetts Medical Society.
Downloaded from nejm.org by heydar dolati on November 20, 2026.

walker. Additional laboratory tests were ordered, along with electromyography. Treatment with gabapentin was initiated, and she was instructed to wear compression stockings on both legs.

One day after this visit, fever developed at night, with temperatures that ranged from 38.0 to 39.0°C and were accompanied by night sweats but no rigors. During the next week, fever persisted and the leg symptoms worsened, which prompted the patient to present to the emergency department of this hospital for evaluation.

On examination, the oral temperature was 37.7°C, the blood pressure 95/40 mm Hg, the heart rate 103 beats per minute, the respiratory rate 16 breaths per minute, and the oxygen saturation 97% while the patient was breathing ambient air. The weight was 54 kg, and the body-mass index (the weight in kilograms divided by the square of the height in meters) was 23. The patient appeared fatigued but was not in distress. No jugular venous distention was present. Fine basilar crackles were noted in both lungs on auscultation, but no cardiac murmur or friction rub was observed. She had prominent pitting edema in both legs up to the shins, with no rash. On motor testing, dorsiflexion was absent in both feet; strength was 5/5 on plantarflexion and knee extension on both sides. Sensation to light touch was absent in the dorsum of the right foot and was normal in the left foot. The patellar reflexes were normal, and the ankle reflexes were mildly diminished.

The blood sodium level was 129 mmol per liter (reference range, 135 to 145); the blood levels of other electrolytes, urea nitrogen, and creatinine were normal. Urinalysis showed 1+ protein (reference value, negative), and microscopic examination of the sediment revealed 6 to 9 red cells per high-power field (reference range, 0 to 2). The ratio of total protein to creatinine in urine was 680 mg per gram (reference value, <150). The erythrocyte sedimentation rate was elevated (79 mm per hour; reference range, 0 to 19), as was the C-reactive protein level (149 mg per liter; reference value, <8).

A complete blood count was notable for a hemoglobin level of 8.4 g per deciliter (reference range, 12.0 to 16.0) with a normal mean corpuscular volume, a platelet count of 684,000 per microliter (reference range, 150,000 to 450,000), and a white-cell count of 16,090 per microliter (reference range, 4000 to 11,000). The ferritin level was elevated, and the total iron-binding capacity was low. Serum protein electrophoresis showed no monoclonal spike, and immunoglobulin levels were normal, as was the ratio of kappa to lambda light chains. The thyrotropin and NT-proBNP levels were normal; the creatine kinase level was low. Screening tests for human immunodeficiency virus (HIV) infection, syphilis, hepatitis B virus (HBV) infection, and hepatitis C virus (HCV) infection were negative. Other laboratory test results are shown in Table 1.

Dr. Monica Cheng: Chest radiography (Fig. 1) showed biapical pleural and parenchymal scarring, findings that most likely reflect previous tuberculosis, as well as diffuse bilateral reticular opacities, without focal airspace consolidation, lymphadenopathy, or pleural effusion. Evidence of a previous mastectomy of the right breast was present, with surgical clips seen in the right axilla.

Dr. Nguyen: Blood specimens were obtained for culture. Treatment with intravenous vancomycin, ceftriaxone, and lactated Ringer's solution was initiated.

The patient reported severe fatigue, ongoing pain and weakness in the legs, and numbness in the feet that was not ascending. During the past 6 weeks, she had had anorexia and an unintentional weight loss of 7 kg. She also noted progressive darkening of her urine during the past week. The patient reported no back pain or radicular symptoms in the legs. A review of systems was negative for cough, dyspnea, orthopnea, abdominal distention, epistaxis, hematochezia, melena, hematuria, arthralgias, sicca symptoms, eye redness, rash, hair loss, and oral ulcers.

The patient's medical history was notable for osteoporosis, as well as ductal carcinoma in situ of the right breast, which was negative for estrogen receptors, progesterone receptors, and human epidermal growth factor receptor 2. Annual mammography of the left breast had been unremarkable. Fecal nucleic acid testing for colorectal carcinoma that had been performed in the past year was negative. Medications included gabapentin, calcium carbonate, and cholecalciferol. She had no known allergies or adverse reactions to medications.

The patient was born in South America and had moved to Massachusetts 30 years before the

The New England Journal of Medicine is produced by NEJM Group, a division of the Massachusetts Medical Society.
Downloaded from nejm.org by heydar dolati on November 20, 2026.

Table 1. Laboratory Data.*

Variable	Reference Range, Adults, Other Hospital	3 Wk before Current Presentation, Other Hospital	Reference Range, Adults, This Hospital†	On Current Presentation, This Hospital
Blood				
Hemoglobin (g/dl)	11.8–16.0	10.2	12.0–16.0	8.4
Hematocrit (%)	36.0–47.0	32.5	41.0–53.0	26.6
Mean corpuscular volume (fl)	80–97	89	80–100	86
White-cell count (per μl)	4000–11,000	10,600	4000–11,000	16,090
Differential count (per μl)				
Neutrophils	—	—	1800–7700	12,380
Lymphocytes	—	—	1000–4800	1960
Monocytes	—	—	200–1200	1410
Eosinophils	—	—	0–900	190
Basophils	—	—	0–300	70
Platelet count (per μl)	150,000–400,000	584,000	150,000–450,000	684,000
Sodium (mmol/liter)	135–145	135	135–145	129
Potassium (mmol/liter)	3.1–5.0	3.8	3.4–5.1	4.3
Chloride (mmol/liter)	98–110	99	98–107	104
Carbon dioxide (mmol/liter)	19–28	25	23–31	26
Urea nitrogen (mg/dl)	7–25	13	6–23	17
Creatinine (mg/dl)	0.50–1.10	0.52	0.50–1.00	0.70
Calcium (mg/dl)	8.0–10.5	8.7	8.5–10.5	8.5
Glucose (mg/dl)	70–100	82	70–99	98
Aspartate aminotransferase (U/liter)	13–35	28	9–32	32
Alanine aminotransferase (U/liter)	9–67	16	7–33	29
Alkaline phosphatase (U/liter)	25–100	86	40–130	114
Total bilirubin (mg/dl)	0.3–1.2	0.8	0.0–1.2	0.6
Direct bilirubin (mg/dl)	—	—	0.0–0.3	0.3
Albumin (g/dl)	3.5–5.0	3.5	3.5–5.2	2.8
Globulin (g/dl)	1.9–4.1	3.3	1.9–4.1	3.7
N-terminal pro–B-type natriuretic peptide (pg/ml)	0–899	488	0–900	228

The New England Journal of Medicine is produced by NEJM Group, a division of the Massachusetts Medical Society.
Downloaded from nejm.org by heydar dolati on November 20, 2026.

Creatine kinase (U/liter)	—	—	26–192	19
Thyrotropin (μIU/ml)	—	—	0.40–5.90	2.68
Iron (μg/dl)	—	—	28–170	12
Total iron-binding capacity (μg/dl)	—	—	220–460	134
Transferrin saturation (%)	—	—	14–50	7
Ferritin (μg/liter)	—	—	30–150	1033
IgG (mg/dl)	—	—	700–1600	988
IgA (mg/dl)	—	—	70–400	178
IgM (mg/dl)	—	—	40–230	114
Free kappa light chain (mg/liter)	—	—	3.3–19.4	25.8
Free lambda light chain (mg/liter)	—	—	5.7–26.3	23.3
Kappa:lambda ratio	—	—	0.26–1.65	1.11
Serum protein electrophoresis	—	—	Negative for monoclonal component	Negative for monoclonal component
Urine				
Color	Yellow	Yellow	Yellow	Yellow
Clarity	Clear	Clear	Clear	Clear
pH	5.0–8.0	5.5	5.0–9.0	6.5
Specific gravity	1.005–1.030	1.016	1.001–1.035	1.020
Glucose	Negative	Negative	Negative	Negative
Ketones	Negative	Negative	Negative	Negative
Leukocyte esterase	Negative	Negative	Negative	Negative
Nitrite	Negative	Negative	Negative	Negative
Blood	Negative	Negative	Negative	1+
Protein	Negative	Negative	Negative	1+
Erythrocytes (per high-power field)	0–2	0	0–2	6–9
Leukocytes (per high-power field)	<10	0	<10	0
Bacteria	None	None	None	None

* To convert the values for urea nitrogen to millimoles per liter, multiply by 0.357. To convert the values for creatinine to micromoles per liter, multiply by 88.4. To convert the values for calcium to millimoles per liter, multiply by 0.250. To convert the values for glucose to millimoles per liter, multiply by 0.05551. To convert the values for bilirubin to micromoles per liter, multiply by 17.1. To convert the values for iron and iron-binding capacity to micromoles per liter, multiply by 0.1791.

† Reference values are affected by many variables, including the patient population and the laboratory methods used. The ranges used at Massachusetts General Hospital are for adults who are not pregnant and do not have medical conditions that could affect the results. They may therefore not be appropriate for all patients.

The New England Journal of Medicine is produced by NEJM Group, a division of the Massachusetts Medical Society.
Downloaded from nejm.org by heydar dolati on November 20, 2026.

current presentation. She resided with friends and had no pets. She was divorced and had an adult child, who had recently traveled from South America to help care for her. Before the onset of her symptoms, the patient had been able to perform activities of daily living independently, without the use of assistive devices. She had smoked one or two cigarettes during social activities for 10 years but had quit smoking 20 years before the current presentation. She did not drink alcohol or use recreational drugs. She had no family history of cancer or autoimmune diseases.

A diagnostic test was performed.

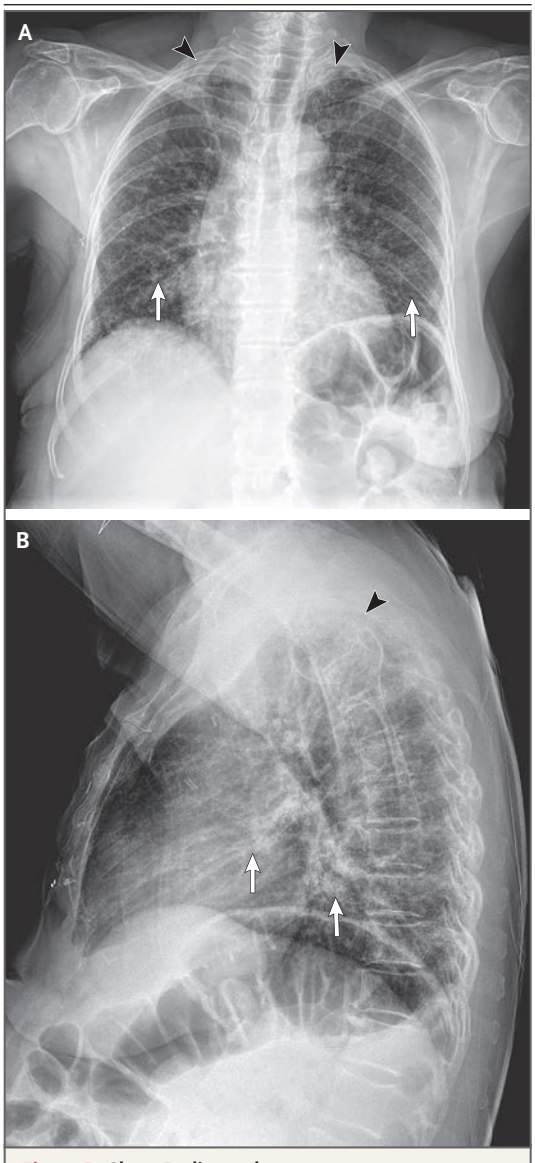

Figure 1. Chest Radiographs.

Posteroanterior and lateral chest radiographs (Panels A and B, respectively) show biapical pleural and parenchymal scarring (arrowheads) and diffuse bilateral reticular opacities (arrows).

DIFFERENTIAL DIAGNOSIS

Dr. Michael P. Janjigian: This 73-year-old woman presented with a subacute process that was characterized by pedal edema and sensorimotor neuropathy, along with constitutional symptoms. She was found to have fever, low blood pressure, tachycardia, foot drop on both sides, proteinuria that was not in the nephrotic range, microscopic hematuria, and elevated levels of acute-phase reactants. Chest radiography showed possible evidence of previous infection with *Mycobacterium tuberculosis*, as well as reticular opacities in both lungs and architectural distortion suggestive of structural lung disease.

Although many of this patient's laboratory test results are abnormal, the elevated levels of ferritin and C-reactive protein and the hematologic anomalies can be categorized as nonspecific markers of systemic inflammation. Looking beyond these results, it seems that this inflammatory disease process shows a particular predilection for the lungs, kidneys, and peripheral nervous system. Further consolidation of disease patterns into syndromes with increased specificity for an underlying process can greatly refine the problem representation to both build and subsequently narrow the differential diagnosis.

PERIPHERAL NEUROPATHY

Peripheral neuropathy can be categorized as a distal symmetric polyneuropathy, such as that caused by diabetes or alcohol use, or as an atypical peripheral neuropathy such as mononeuritis multiplex. In this patient, the relatively rapid disease course — beginning with neuropathic pain in both legs and progressing to severe bilateral foot drop with decreased ankle reflexes and asymmetric findings on sensory examination — suggests a mixed small- and large-fiber peripheral neuropathy, which favors mononeuritis multiplex over distal symmetric polyneuropathy. In the absence of heart failure, nephrotic-range proteinuria, culprit medications, or evident thrombosis, the pedal edema can be considered to be part of the inflammatory process, rather than an independent finding.

The New England Journal of Medicine is produced by NEJM Group, a division of the Massachusetts Medical Society.
Downloaded from nejm.org by heydar dolati on November 20, 2026.

HEMATURIA

The development of hematuria and proteinuria is consistent with glomerulonephritis, and the findings on chest radiography are suggestive of interstitial lung disease. The differential diagnosis for this patient can thus be constructed over the scaffolding of the overlap of processes that lead to mononeuritis multiplex, glomerulonephritis, and interstitial lung disease. The frame can then be narrowed through a systematic approach in which pertinent positive and negative attributes are weighed.

CANCER

Cancer can cause leg weakness through multiple mechanisms, and the patient's history of cancer increases her risk of recurrence or new neoplasms. Possible mechanisms include direct infiltration of the nervous system from leukemia or lymphoma, compression of nerve roots by metastases, and paraneoplastic processes such as Lambert–Eaton myasthenic syndrome (LEMS) or encephalomyelitis. LEMS is most commonly caused by small-cell lung cancer, which could be present in this patient, given the abnormal chest radiographs; however, LEMS classically causes proximal weakness that is more severe than distal weakness. The bilateral nature of the patient's foot drop would require the presence of symmetric spinal metastases, and furthermore, it would be unlikely for the breast cancer to recur after 20 years. As such, solid tumors do not provide an adequate explanation for this patient's presentation.

Clonal plasma-cell dyscrasias, including POEMS syndrome (polyneuropathy, organomegaly, endocrinopathy, M protein, and skin changes) and amyloid light-chain amyloidosis, could explain a systemic process associated with neuropathy and edema. However, in this patient, the results of serum protein electrophoresis were normal, as was the ratio of kappa to lambda, findings that rule out these conditions.

ENDOCRINE DISORDERS

Diabetic neuropathy is a highly prevalent condition, and it commonly manifests as distal symmetric polyneuropathy. In addition, in rare cases, diabetes mellitus can result in a radiculoplexus neuropathy that can cause foot drop, but this patient has no other radicular symptoms or examination findings suggestive of this phenomenon, such as proximal muscle atrophy.[1] It is important to note that she did not have evidence of current or previous diabetes. Hypothyroidism can cause edema and sensory neuropathy; however, the clinical syndrome in this patient was otherwise inconsistent with hypothyroidism, and the thyroid test results were normal.

INFECTION

The patient was raised in South America, which puts her at risk for multiple infections that can cause neuropathy. Leprosy is a well-known cause of peripheral neuropathy that can also lead to glomerulonephritis, but the characteristic skin findings were absent in this patient, and leprosy does not cause severe systemic inflammation. *M. tuberculosis* infection could be the cause of her constitutional and pulmonary findings, particularly given the possible evidence of previous tuberculosis on chest imaging, but the pattern of sensory and motor neuropathy would not be typical of this infection. Chagas disease would cause a chronic illness that is predominantly associated with sensory neuropathy, and infection with human T-lymphotropic virus type 1 would cause a spastic paralysis predominantly affecting the proximal muscles; therefore, these diagnoses are unlikely in this case.

RHEUMATOLOGIC DISEASES

The patient's age, constitutional symptoms, and subacute process suggestive of mononeuritis multiplex, glomerulonephritis, and interstitial lung disease make a rheumatologic disease the most likely cause of her condition.

Vasculitis can be secondary to systemic lupus erythematosus (SLE), Sjögren's disease, and mixed cryoglobulinemia. Sjögren's disease is an unlikely diagnosis in this patient, given the absence of sicca symptoms and a predominantly sensory neuropathy. Mixed cryoglobulinemia is also unlikely, given the absence of risk factors (chronic HCV, HBV, or HIV infection) and of arthralgias, cutaneous ulcers, or palpable purpura on the legs. SLE is associated with protean manifestations that could explain the multiorgan involvement in this patient; however, she did not have many of the other classic features of SLE, which makes this diagnosis unlikely. In addition, although an anti–glomerular basement membrane disease such as Goodpasture syndrome

The New England Journal of Medicine is produced by NEJM Group, a division of the Massachusetts Medical Society.
Downloaded from nejm.org by heydar dolati on November 20, 2026.

could explain her lung and kidney findings, it would not explain her neuropathy.

Sarcoidosis is a cause of mononeuritis multiplex that should be considered in this patient, especially given her lung and kidney involvement. However, the onset of sarcoidosis in adults older than 70 years of age is rare,[2] and the combination of bilateral mononeuritis multiplex and glomerulonephritis would be unusual for sarcoidosis.

Primary vasculitides that could affect small and medium-sized vessels and lead to a balanced mononeuritis multiplex include antineutrophil cytoplasmic antibody (ANCA)–associated vasculitides and polyarteritis nodosa. Polyarteritis nodosa typically manifests in middle-aged and older adults with constitutional symptoms and can involve the kidneys, skin, joints, muscles, nerves, and gastrointestinal tract, usually with sparing of the lungs. Clinical neuropathy is a common feature of polyarteritis nodosa that occurs in approximately 75% of patients.[3] Kidney involvement in patients with polyarteritis nodosa, when present, results from microaneurysms in the kidney vessels that lead to renin-dependent hypertension, hematuria without red-cell casts, and nonnephrotic proteinuria.[4] Polyarteritis nodosa is an unlikely diagnosis in this patient, given the absence of hypertension, skin findings, and gastrointestinal or vascular pathologic features and the presence of suspected interstitial lung disease.

ANCA-associated vasculitides, particularly eosinophilic granulomatosis with polyangiitis (EGPA), granulomatosis with polyangiitis (GPA), and microscopic polyangiitis (MPA), are well-known causes of systemic symptoms with involvement of the peripheral nerves, kidneys, and lungs. EGPA is unlikely in this patient because of the normal eosinophil count and absence of antecedent atopic features. With GPA, kidney involvement is commonly manifested by glomerulonephritis, but the peripheral nerves are involved in only approximately 20 to 25% of patients; by contrast, approximately 40 to 50% of patients with MPA have peripheral-nerve involvement.[3] Furthermore, this patient did not have sinus symptoms, ulcers, or palpable purpura, which are common features of GPA. Both MPA and GPA can cause glomerulonephritis; however, GPA is usually associated with a more aggressive course of disease.[5] Pulmonary manifestations are common in all ANCA-associated vasculitides but may not be prominent early in the disease course. Given this patient's age and syndrome of constitutional symptoms, including mononeuritis multiplex, glomerulonephritis, and interstitial lung disease, an ANCA-associated vasculitis is the most likely diagnosis, with MPA (Fig. 2) being more likely than GPA.

Figure 2 (facing page). Clinical Features of Microscopic Polyangiitis at Diagnosis.

Shown are the most common clinical manifestations of microscopic polyangiitis at diagnosis, including the incidence of certain constitutional symptoms and of renal, pulmonary, cutaneous, and neurologic involvement. ANCA denotes antineutrophil cytoplasmic antibody, and MPO myeloperoxidase. Adapted from Casal Moural et al.[6]

To confirm the diagnosis of MPA, testing for ANCA with antigen specificity is warranted. Myeloperoxidase (MPO) positivity would support the diagnosis of MPA, whereas proteinase 3 (PR3) positivity would support GPA. CT of the chest should be performed to characterize the lung features. A kidney biopsy would establish the pattern and stage of injury; however, it would not be necessary in this patient if MPA is considered to be the most likely diagnosis and circulating ANCAs are present.

DR. MICHAEL P. JANJIGIAN'S DIAGNOSIS

Microscopic polyangiitis.

DIAGNOSTIC TESTING

Dr. Cheng: Subsequent chest CT, performed after the administration of intravenous contrast material (Fig. 3), revealed diffuse subpleural reticulations that were most prominent in the lower lungs, traction bronchiectasis and bronchiolectasis, and ground-glass opacities but no honeycombing.

Dr. Cory A. Perugino: The diagnostic evaluation in this case included two-tiered ANCA testing, which is the standard approach for patients with suspected ANCA-associated vasculitis. The first tier involves testing of permeabilized neutrophils for antibody binding by means of immunofluorescence, which is used to determine whether ANCA is present. Immunofluorescence also

The New England Journal of Medicine is produced by NEJM Group, a division of the Massachusetts Medical Society.
Downloaded from nejm.org by heydar dolati on November 20, 2026.

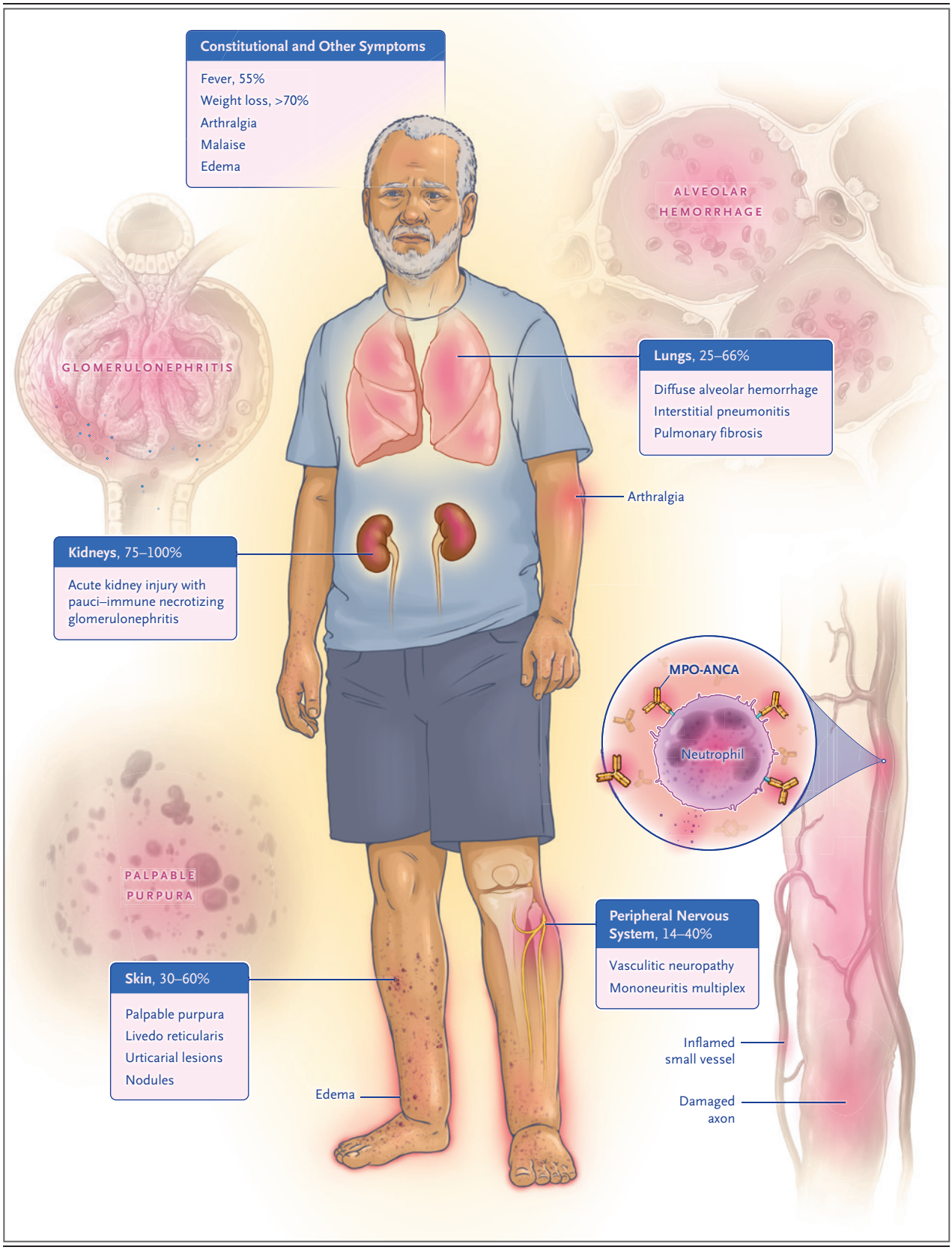

The New England Journal of Medicine is produced by NEJM Group, a division of the Massachusetts Medical Society.
Downloaded from nejm.org by heydar dolati on November 20, 2026.

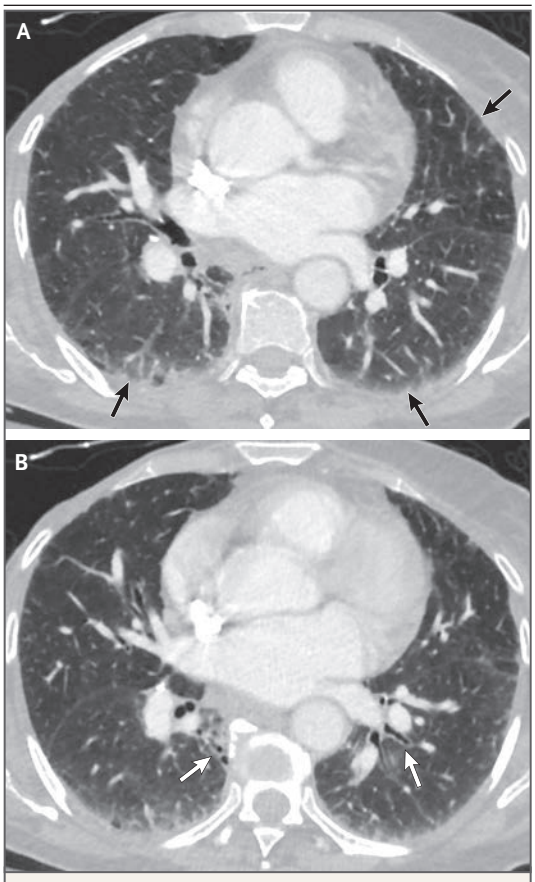

Figure 3. CT of the Chest.

Axial CT images of the chest obtained after the administration of intravenous contrast material (Panels A and B) show diffuse subpleural reticulations predominantly in the lower lungs (Panel A, arrows), traction bronchiectasis and bronchiolectasis (Panel B, arrows), and ground-glass opacities but no honeycombing.

provides qualitative data on the staining pattern, which may be cytoplasmic (c-ANCA) or perinuclear (p-ANCA). Although the c-ANCA pattern often corresponds to antibodies against PR3 and the p-ANCA pattern to antibodies against MPO, it is important to recognize that this test is not antigen-specific. Nonpathogenic antigens expressed by neutrophils, such as lactoferrin, lysozyme, and elastase, can drive ANCA immunofluorescence positivity without being linked to disease.

The second tier involves use of an enzyme-linked immunosorbent assay (ELISA), which is a confirmatory test for ANCA immunofluorescence positivity that can define the specific antigen and titer of ANCA against PR3 or MPO. These specific autoantibodies are strongly associated with ANCA-associated vasculitis and clinical disease.

In this patient, immunofluorescence was positive for ANCA in a p-ANCA staining pattern, and ELISA was positive for anti-MPO antibodies at a titer of 7.5 U per milliliter (reference value, <2.8). The p-ANCA staining pattern and anti-MPO antibodies can be caused by a drug-induced immune response, which is particularly associated with levamisole (a common adulterant of cocaine), methimazole, propylthiouracil, and hydralazine. This patient reported no recreational drug use and was not receiving treatment with any of these medications; thus, the presence of drug-induced ANCA was unlikely.

Testing for rheumatoid factor was positive at a titer of 29 IU per milliliter (reference value, <14), and testing for cyclic anti–citrullinated peptide antibody was negative. The test for rheumatoid factor was thought to be a false positive, given the low titer and the clinical presentation, which was not consistent with rheumatoid arthritis.

Nerve-conduction studies and electromyography confirmed the presence of acute peroneal and tibial neuropathies in both legs. These findings are consistent with mononeuritis multiplex.

Overall, the patient's systemic inflammatory disease presentation, which was characterized by a markedly elevated C-reactive protein level and involvement of multiple sites, including the kidneys, lungs, and peripheral nerves, was most consistent with a necrotizing ANCA-associated vasculitis. The presence of anti-MPO antibodies, interstitial lung disease, and mononeuritis multiplex favors a diagnosis of MPA over GPA.

LABORATORY DIAGNOSIS

Microscopic polyangiitis.

DISCUSSION OF RHEUMATOLOGY MANAGEMENT

Dr. Jonathan S. Hausmann: The management of ANCA-associated vasculitis is divided into two phases: induction of remission to rapidly halt active inflammation and maintenance of remission to prevent relapse of disease. The intensity of the chosen immunosuppressive regimen is determined by the severity of the patient's presentation. This patient presented with disease that is considered to be active and severe,[7] with

The New England Journal of Medicine is produced by NEJM Group, a division of the Massachusetts Medical Society.
Downloaded from nejm.org by heydar dolati on November 20, 2026.

multiple organ-threatening manifestations, including mononeuritis multiplex resulting in acute bilateral foot drop, presumed glomerulonephritis, and interstitial lung disease. The profound weakness resulting from necrotizing vasculitis of the vasa nervorum constitutes a neurologic emergency; delayed treatment can lead to irreversible ischemic axonal injury, permanent deficits, and impaired quality of life.[8]

INDUCTION OF REMISSION

Historically, cyclophosphamide paired with systemic glucocorticoid therapy was the standard approach to inducing remission in patients with ANCA-associated vasculitis, effectively transforming an often-fatal disease into a manageable one.[9] However, in the landmark RAVE trial,[10] rituximab was shown to be noninferior to cyclophosphamide and has since become the preferred induction agent for many patients, given its more favorable safety profile.

For this patient, rituximab was the preferred choice for several reasons. First, she is a frail older adult with osteoporosis, for whom the use of cyclophosphamide and prolonged high-dose glucocorticoid therapy is particularly hazardous.[11] Second, and perhaps most important, rituximab is the preferred induction agent for patients with ANCA-associated vasculitis who have interstitial lung disease. Among such patients, who usually have an MPO-ANCA–specific MPA phenotype, the risk of death is approximately three times as high as the risk among patients with ANCA-associated vasculitis without interstitial lung disease; this increased risk of death is largely driven by progressive fibrotic lung disease.[12,13] Data from a retrospective study suggested that rituximab was associated with greater improvements in forced vital capacity than other immunosuppressive therapies.[14]

GLUCOCORTICOID-SPARING STRATEGY

A major trend in the management of ANCA-associated vasculitis is the minimization of glucocorticoid exposure to mitigate severe adverse effects, such as osteoporosis and life-threatening infections. The PEXIVAS trial[15] and the LoVAS trial[16] showed that reduced-dose regimens of glucocorticoids yielded outcomes equivalent to those of traditional high-dose regimens.

Avacopan, an oral selective C5a receptor antagonist, has the potential to reduce glucocorticoid exposure, which is essential in lowering the risk of infection. Mitigating this risk was especially important for this patient, since infection is a major complication and cause of death in patients with interstitial lung disease.

PATIENT COURSE AND MAINTENANCE OF REMISSION

To induce remission, the patient received treatment with boluses of intravenous methylprednisolone for 3 days, followed by a rapidly tapering course of oral prednisone over the course of 4 weeks. Two doses of rituximab were administered, and avacopan therapy was started. To manage the secondary risks of her treatment, she was given zoledronic acid for prevention of glucocorticoid-induced bone loss, and she received trimethoprim–sulfamethoxazole for prophylaxis against *Pneumocystis jirovecii* pneumonia. She was referred to physical therapy and fitted with ankle–foot orthoses for her bilateral foot drop.

FOLLOW-UP

Dr. Hausmann: At the time of the patient's 1-month follow-up visit, she had successfully completed the tapering course of glucocorticoids, with no progression of her weakness or numbness. Because the ischemic damage to the peripheral nerves was severe, she had only minimal improvement in foot dorsiflexion and continued to rely on a walker for ambulation. To maintain remission and prevent disease flares, we planned to administer rituximab infusions every 6 months, a strategy shown to be superior to maintenance therapy with azathioprine,[17] and to continue therapy with avacopan for 1 year.

FINAL DIAGNOSIS

Microscopic polyangiitis.

CASE RECORDS EDITORS' NOTE

The patient was treated with avacopan because, at the time, the available evidence supported its efficacy. In light of emerging concerns regarding the pivotal trial[18] and the possibility that the drug may be withdrawn from the market, its use is unlikely to be recommended going forward.

This case was presented at the Medicine Case Conference.

Disclosure forms provided by the authors are available with the full text of this article at NEJM.org.

The New England Journal of Medicine is produced by NEJM Group, a division of the Massachusetts Medical Society.
Downloaded from nejm.org by heydar dolati on November 20, 2026.

AUTHOR INFORMATION

[1]Department of Medicine, NYU Grossman School of Medicine, New York; [2]Department of Radiology, Massachusetts General Hospital, Boston; [3]Department of Radiology, Harvard Medical School, Boston; [4]Department of Medicine, Massachusetts General Hospital, Boston; [5]Department of Medicine, Harvard Medical School, Boston; [6]Department of Pediatrics, Boston Children's Hospital, Boston.

REFERENCES

1. Geha R, Omid-Fard N, Slama MCC, Reda HM. Case Records of the Massachusetts General Hospital (Case 18-2026). N Engl J Med 2026;394:2460-9.

2. Valeyre D, Prasse A, Nunes H, Uzunhan Y, Brillet P-Y, Müller-Quernheim J. Sarcoidosis. Lancet 2014;383:1155-67.

3. Gwathmey KG, Burns TM, Collins MP, Dyck PJB. Vasculitic neuropathies. Lancet Neurol 2014;13:67-82.

4. Stone JH. Polyarteritis nodosa. JAMA 2002;288:1632-9.

5. Kronbichler A, Bajema IM, Bruchfeld A, Mastroianni Kirsztajn G, Stone JH. Diagnosis and management of ANCA-associated vasculitis. Lancet 2024;403:683-98.

6. Casal Moura M, Merkel PA, Jayne D, et al. Challenges in the diagnosis, classification and prognosis of ANCA-associated vasculitis. Nat Rev Rheumatol 2025;21:719-36.

7. Chung SA, Langford CA, Maz M, et al. 2021 American College of Rheumatology/Vasculitis Foundation guideline for the management of antineutrophil cytoplasmic antibody-associated vasculitis. Arthritis Rheumatol 2021;73:1366-83.

8. Collins MP, Hadden RDM, Luqmani RA. Vasculitic neuropathy-related disability, pain, quality of life, and autonomic symptoms: a survey of 312 patients. Rheumatology (Oxford) 2024;63:2791-8.

9. Fauci AS, Wolff SM. Wegener's granulomatosis: studies in eighteen patients and a review of the literature. Medicine (Baltimore) 1973;52:535-61.

10. Stone JH, Merkel PA, Spiera R, et al. Rituximab versus cyclophosphamide for ANCA-associated vasculitis. N Engl J Med 2010;363:221-32.

11. Kidney Disease: Improving Global Outcomes (KDIGO) CKD Work Group. KDIGO 2024 clinical practice guideline for the evaluation and management of chronic kidney disease. Kidney Int 2024;105:Suppl 4:S117-S314.

12. Zhou P, Ma J, Wang G. Impact of interstitial lung disease on mortality in ANCA-associated vasculitis: a systematic literature review and meta-analysis. Chron Respir Dis 2021;18:1479973121994562.

13. Narváez J, Maymó P. Isolated antineutrophil cytoplasmic antibody-associated interstitial lung disease: a systematic review of an emerging condition. Autoimmun Rev 2026;25:104037.

14. Chalkia A, Kotnik M, Sadler TJ, et al. Interstitial lung disease in antineutrophil cytoplasmic antibody-associated vasculitis: a European multicenter study. Arthritis Rheumatol 2026;78:1718-30.

15. Walsh M, Merkel PA, Peh C-A, et al. Plasma exchange and glucocorticoids in severe ANCA-associated vasculitis. N Engl J Med 2020;382:622-31.

16. Furuta S, Nakagomi D, Kobayashi Y, et al. Effect of reduced-dose vs high-dose glucocorticoids added to rituximab on remission induction in ANCA-associated vasculitis: a randomized clinical trial. JAMA 2021;325:2178-87.

17. Guillevin L, Pagnoux C, Karras A, et al. Rituximab versus azathioprine for maintenance in ANCA-associated vasculitis. N Engl J Med 2014;371:1771-80.

18. Rubin EJ. Retraction: Jayne DRW et al. Avacopan for the treatment of ANCA-associated vasculitis, N Engl J Med 2021;384:599-609. N Engl J Med. DOI: 10.1056/NEJMe2608684.

Copyright © 2026 Massachusetts Medical Society.

The New England Journal of Medicine is produced by NEJM Group, a division of the Massachusetts Medical Society.
Downloaded from nejm.org by heydar dolati on November 20, 2026.